

# SHARP-SHINNED HAWKS ORAL LESIONS GRADING SYSTEM



An oral examination should be performed on every sharp-shinned hawk, by holding the beak open wide, and with the use of supplemental light if possible.




*Capillaria* lesions typically present as white to yellow caseous plaques that can range in size from pinpoint to very large (4-5mm) and be either discrete single or multiple coalescing lesions.

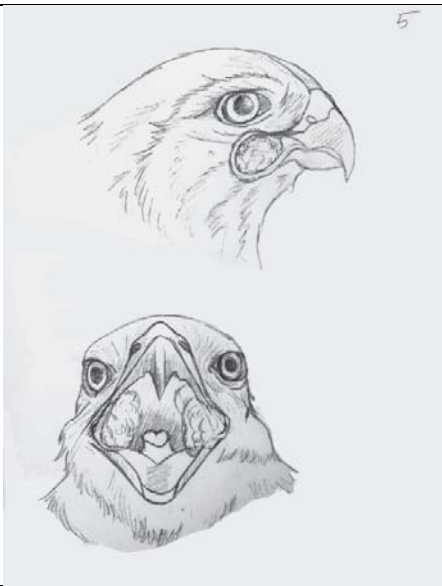
The oral mucosa (pink moist tissue in the mouth) around the lesions may be red, swollen, and irregular, especially in advanced lesions.

In this disease, lesions are primarily focused around the commissures (“gape” or corners of the mouth) and may also be located on either side of the choana (slit-like opening in the roof of the mouth) and on either side of the tongue.

- GRADE 0** No oral lesions/plaques are present.  
Commissures: normal
- GRADE 1** Oral lesions: 1-4 small lesions/plaques (1-2mm each).  
Commissures: normal
- GRADE 2** Oral lesions: 1-4 lesions, with at least one large lesion/plaque (4-5mm diameter).  
Commissures: normal
- GRADE 3** Oral lesions: >4 lesions/plaques, all under 4-5mm in diameter.  
Commissures: Possible mild involvement, but not visible when the beak is closed.
- GRADE 4** Oral lesions: Multiple coalescing lesions/plaques, with at least one >4-5mm diameter.  
Commissures: Presence of lesions visible from the outside when beak is closed, and some distortion is present.
- GRADE 5** Oral lesions: Severe coalescing and large lesions/plaques.  
Commissures: Significant distortion and/or ulceration that is visible when the beak is closed.

GRADE	ORAL LESIONS/PLAQUES	COMMISSURES	
0	None	Normal	
1	1-4 small lesions/plaques 1-2mm diameter each	Normal	

<p><b>2</b></p>	<p>&gt;2 lesions/plaques At least one lesion is large (4-5mm diameter)</p>	<p>Normal</p>	
<p><b>3</b></p>	<p>&gt;2 lesions/plaques At least one lesion is large (4-5mm diameter)</p>	<p>Mild involvement, but not visible when the beak is closed.</p>	
<p><b>4</b></p>	<p>Multiple coalescing lesions/plaques, with at least one &gt;4-5mm diameter.</p>	<p>Presence of lesions visible from outside when beak is closed, and some distortion is present.</p>	

<p>5</p>	<p>Severe large and coalescing lesions/plaques.</p>	<p>Significant distortion and/or ulceration that is visible when the beak is closed.</p>	<p>5</p> 
----------	---	--	---